

Рентгенологический отчет: Зубы 16 — 47

28.11.2019

ФИО пациента: Endo sample 8x8

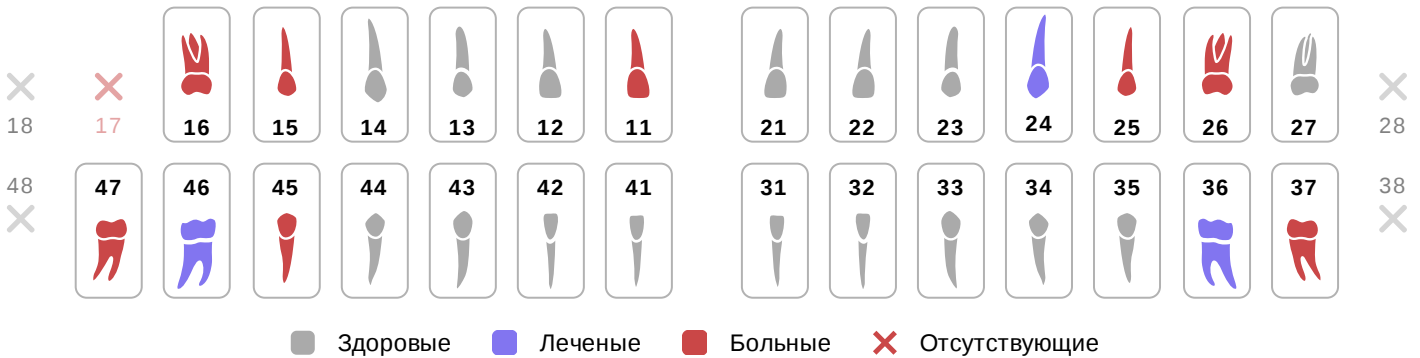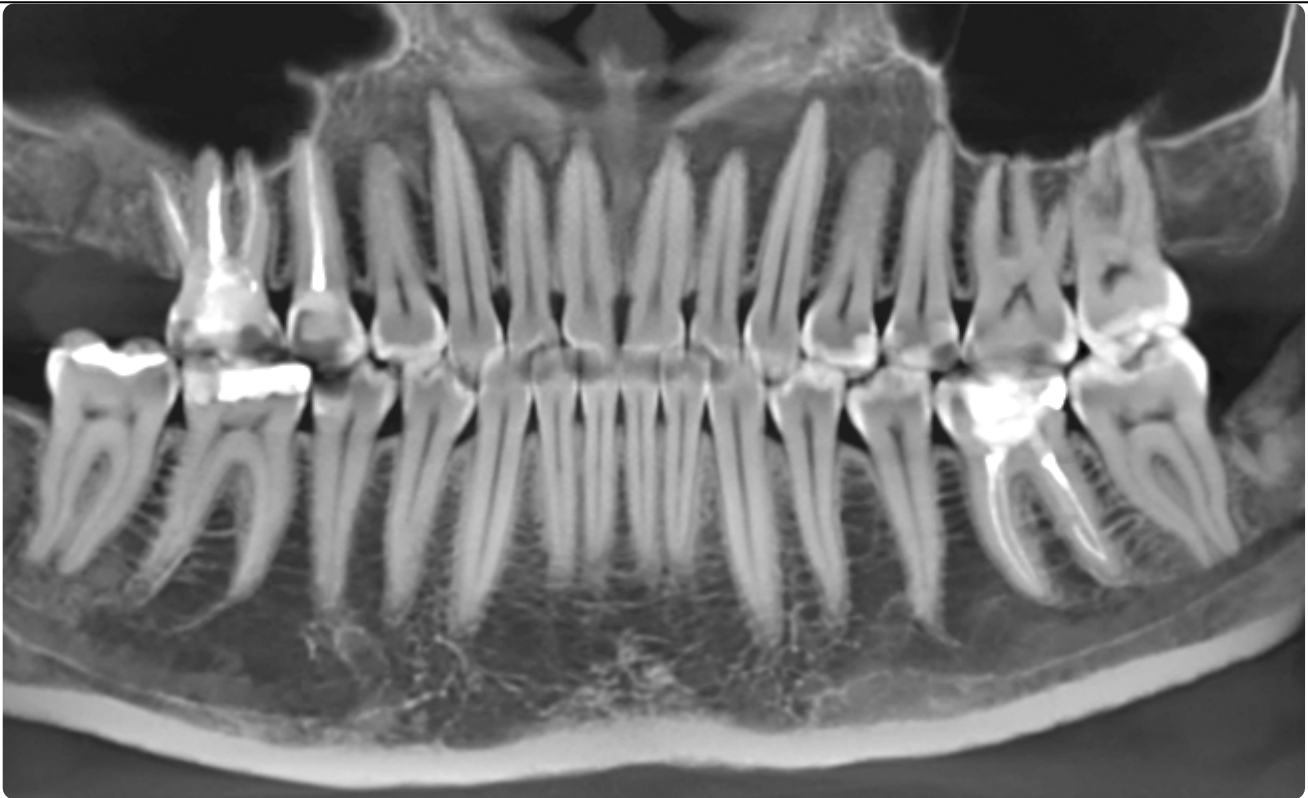ID пациента: 10135986

Возраст: 36

Дата рождения: 1982-12-16

Дата исследования: 2019-11-28

Пол: Женский



Зона интереса

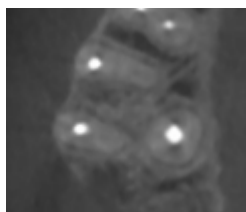


Зуб 16

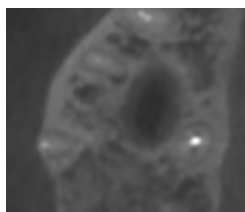
3 корня, 3 канала, Пломба, Признаки кариеса, Зуб эндодонтически лечен,
Каналы запломбированы до верхушек, Пломбировка гомогенна,
Расширение пространства периодонтальной связки у верхушки.



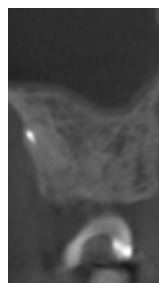
Axial



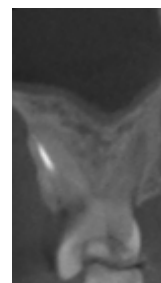
Axial



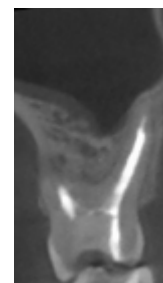
Axial



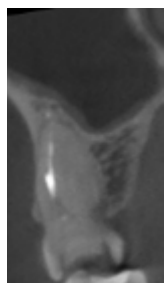
Frontal



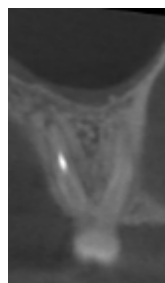
Frontal



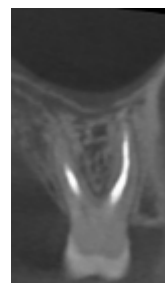Frontal



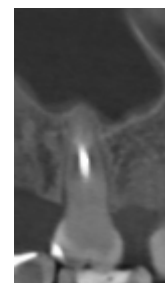
Frontal



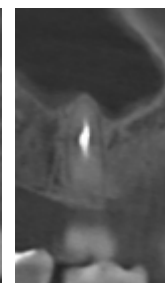
Sagittal



Sagittal



Sagittal

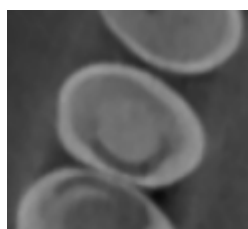


Sagittal

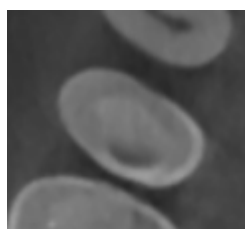


Зуб 15

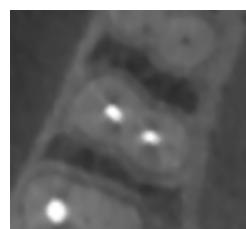
1 корень, 2 канала, Пломба, Признаки кариеса, Зуб эндодонтически лечен,
Каналы запломбированы до верхушек, Пломбировка гомогенна,
Расширение пространства периодонтальной связки у верхушки.



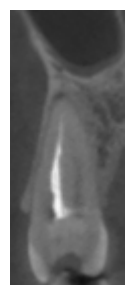Axial



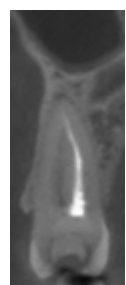Axial



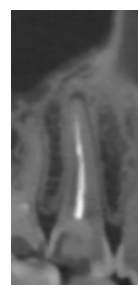
Axial



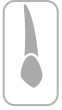Frontal



Frontal

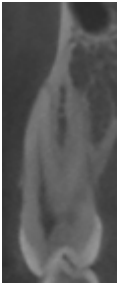

Perio

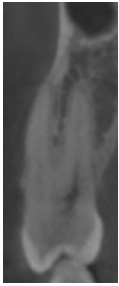

Зуб 14

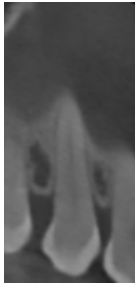
2 корня, 2 канала.



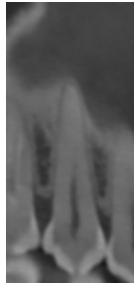Frontal



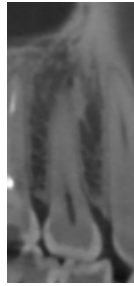Frontal



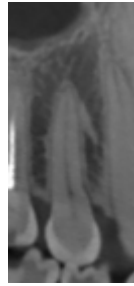
Sagittal



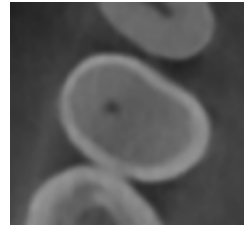
Sagittal



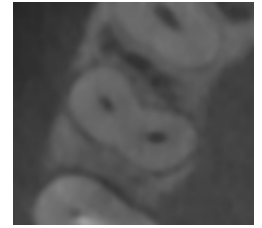
Sagittal




Sagittal



Axial



Axial

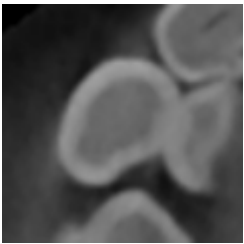


Axial

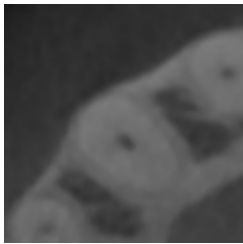


Зуб 13

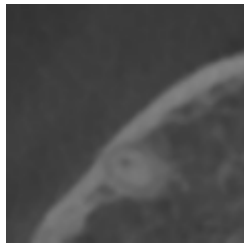
1 корень, 1 канал.



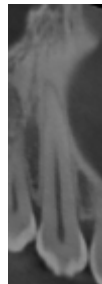
Axial



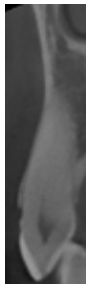Axial



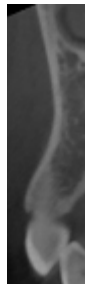
Axial



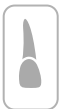Sagittal



Frontal

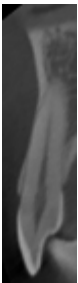

Frontal



Зуб 12


1 корень, 1 канал.



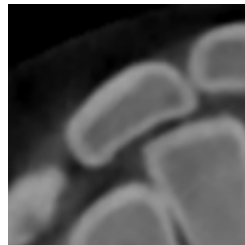
Frontal



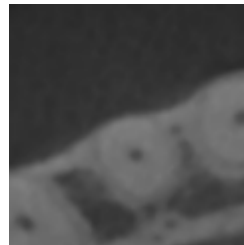Frontal




Sagittal



Axial



Axial

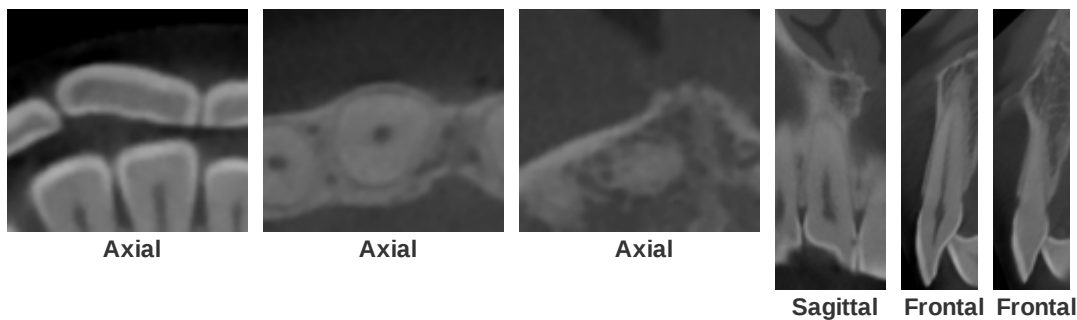


Axial



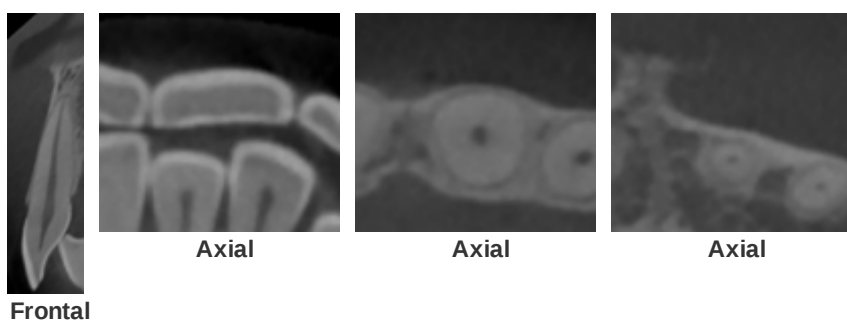
Зуб 11

1 корень, 1 канал, **Признаки кариеса.**



Зуб 21

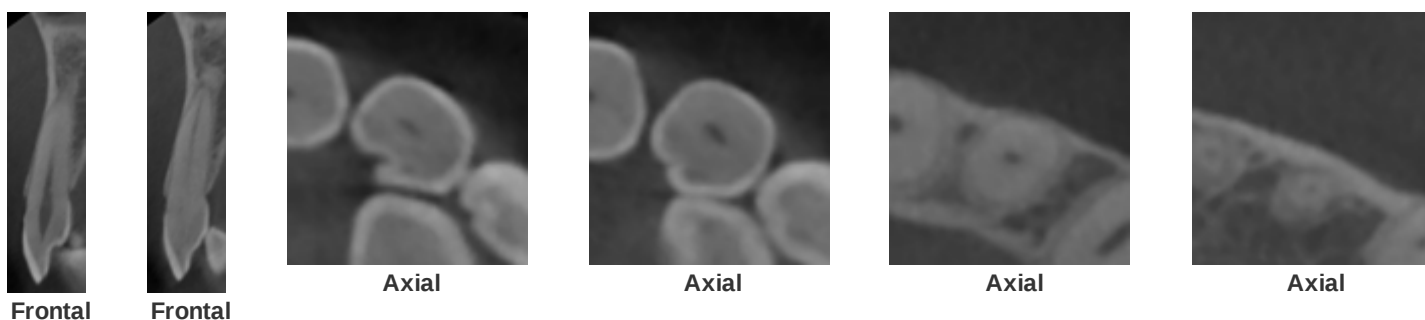
1 корень, 1 канал.



Зуб 22

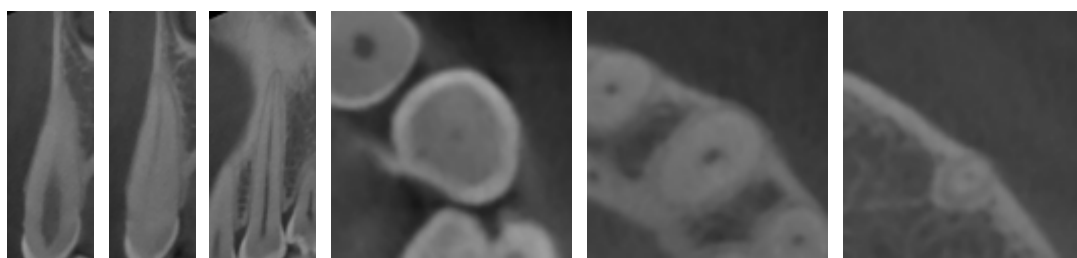
1 корень, 1 канал.

Грув на небной поверхности коронки?



Зуб 23

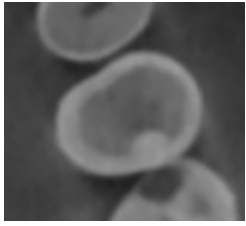
1 корень, 1 канал.





Зуб 24

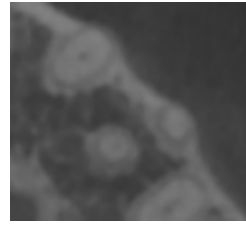
2 корня, 2 канала, Пломба.



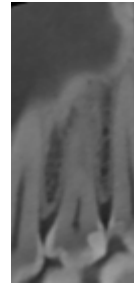
Axial



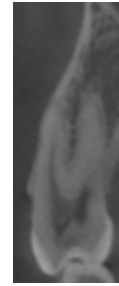
Axial



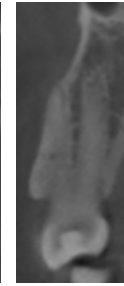
Axial



Sagittal



Frontal



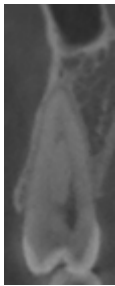
Frontal



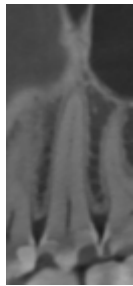
Зуб 25

1 корень, 2 канала, Признаки кариеса.

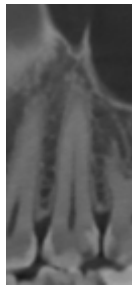■ Нельзя исключить кариес.



Frontal



Sagittal

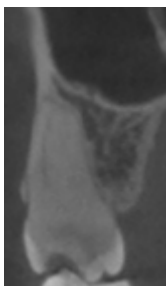


Sagittal

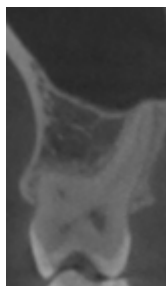

Зуб 26

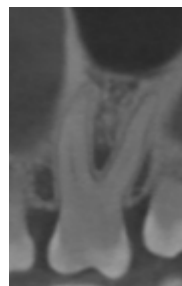
3 корня, 4 канала, Пломба, Признаки кариеса.



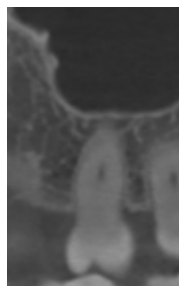
Frontal



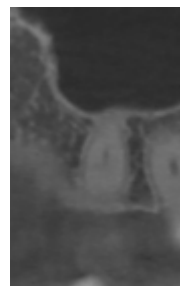
Frontal



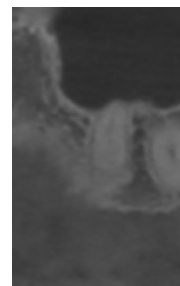
Sagittal



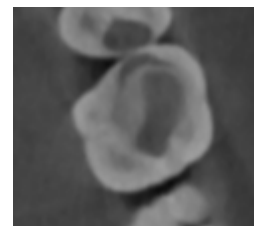
Sagittal



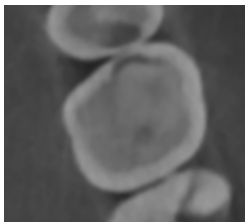
Sagittal



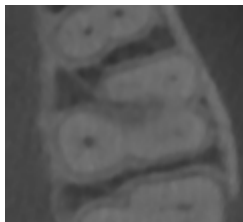
Sagittal



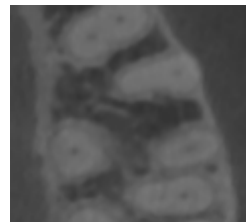
Axial



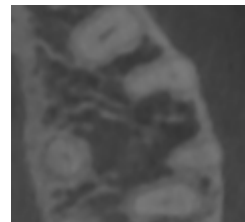Axial



Axial



Axial

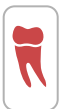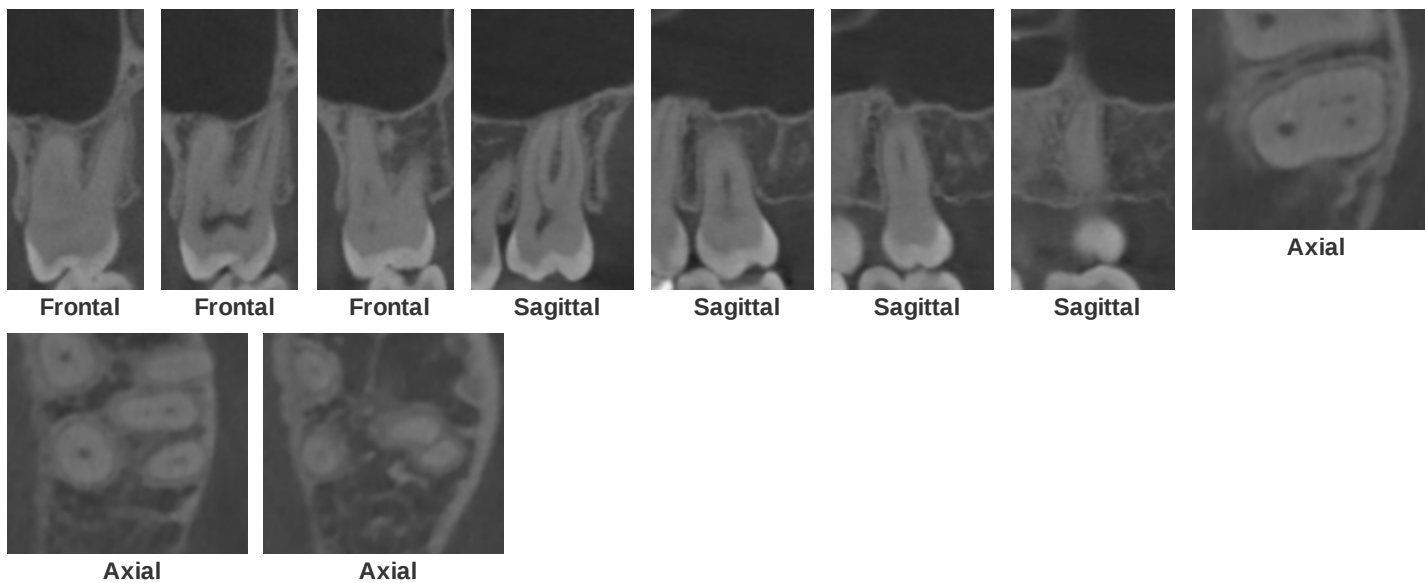


Axial



Зуб 27

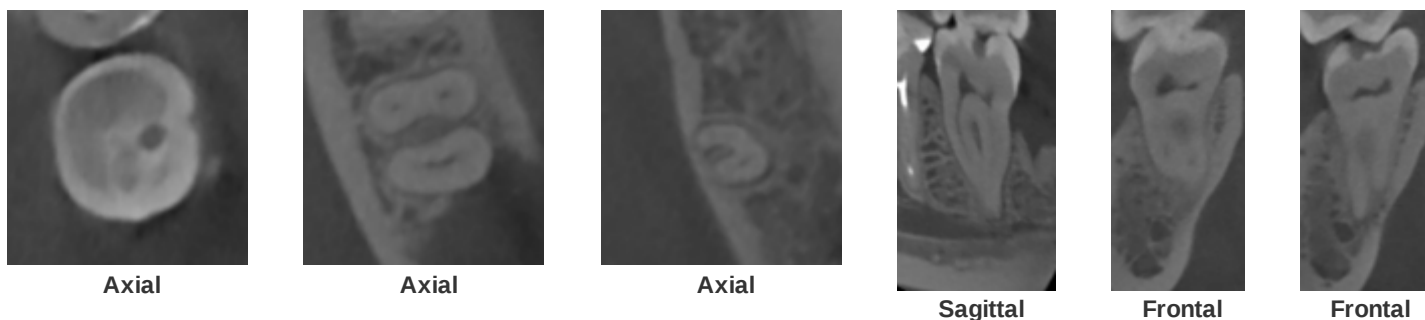3 корня, 4 канала.



Зуб 37

2 корня, 3 канала, **Признаки кариеса,**

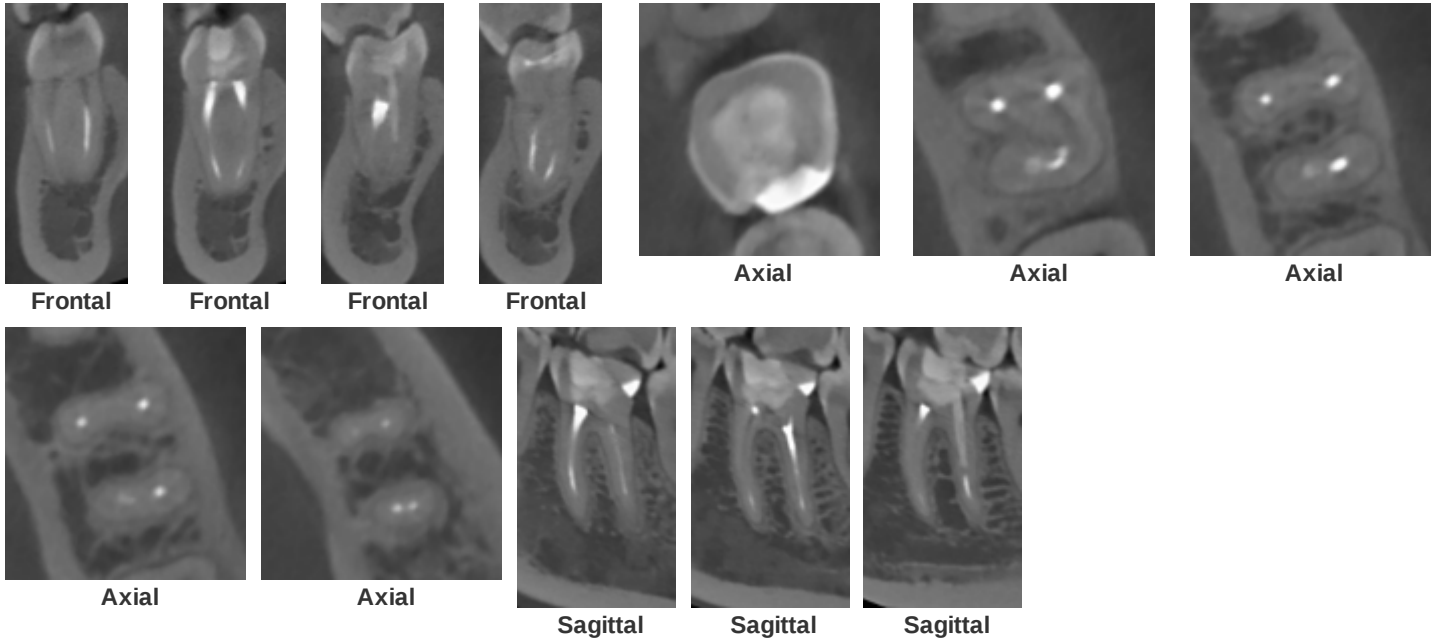
Расширение пространства периодонтальной связки у верхушки.





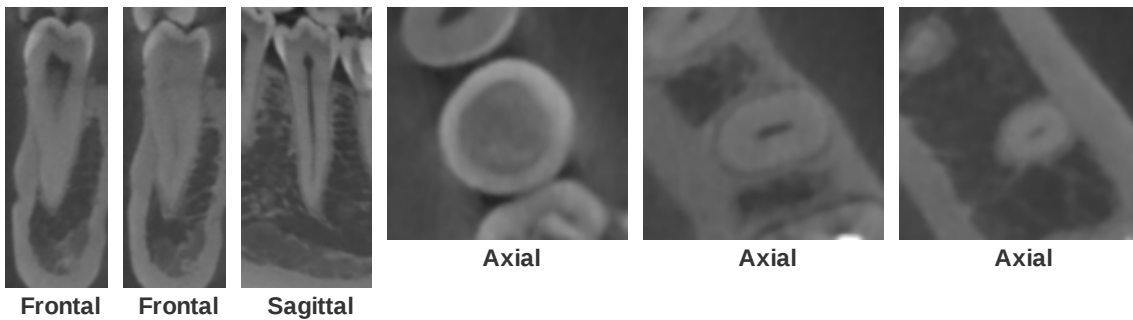
Зуб 36

2 корня, 4 канала, Пломба, Зуб эндодонтически лечен,
Каналы запломбированы до верхушек, Пломбировка гомогенна.




Зуб 35

1 корень, 1 канал.



Зуб 34

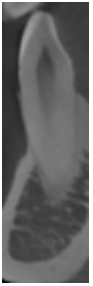1 корень, 1 канал.



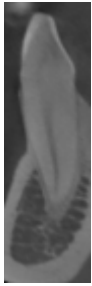


Зуб 33

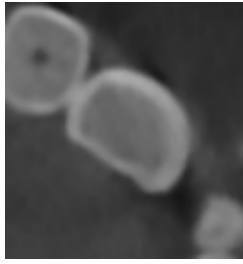
1 корень, 1 канал.



Frontal



Frontal



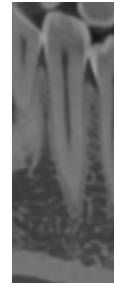
Axial



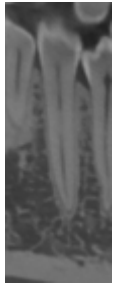Axial



Axial



Sagittal

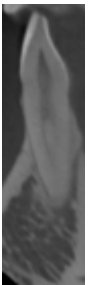


Sagittal

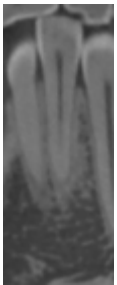


Зуб 32


1 корень, 1 канал.



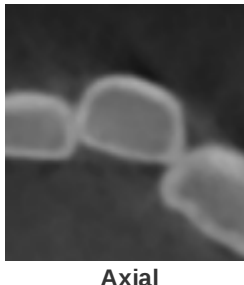
Frontal




Sagittal



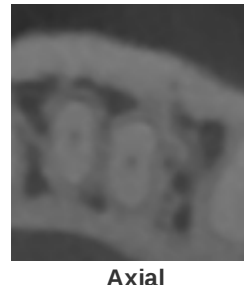
Sagittal



Axial



Axial

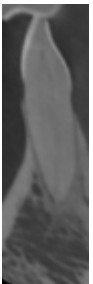


Axial

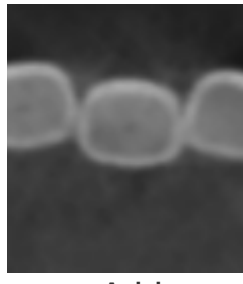


Зуб 31

1 корень, 1 канал.



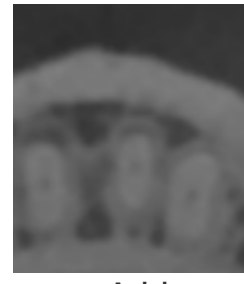
Frontal



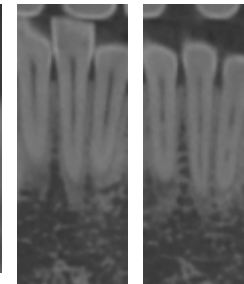
Axial



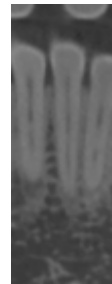
Axial



Axial



Sagittal

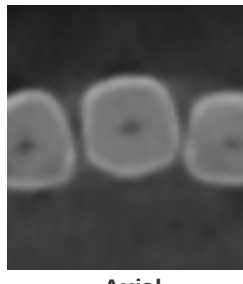
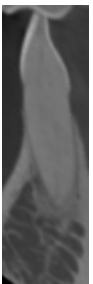

Sagittal



Зуб 41

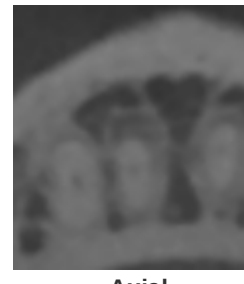1 корень, 1 канал.



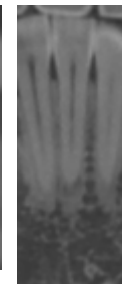
Axial



Axial



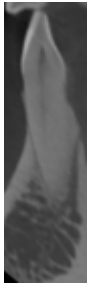Axial



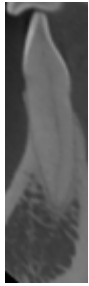

Зуб 42

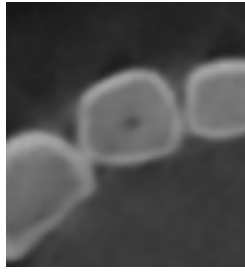
1 корень, 2 канала.



Frontal



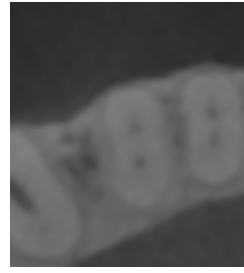Frontal



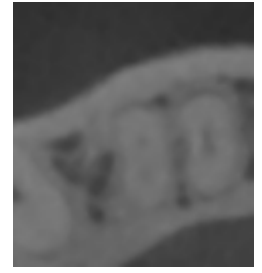Axial



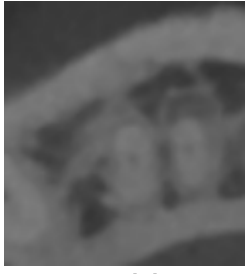Axial



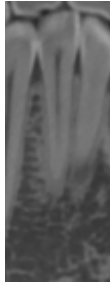Axial



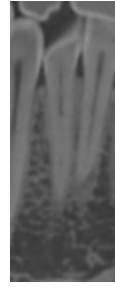
Axial



Axial



Sagittal

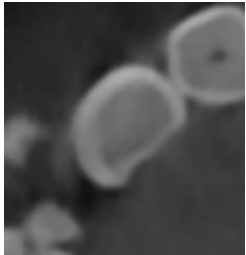


Sagittal

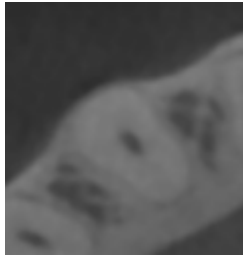


Зуб 43

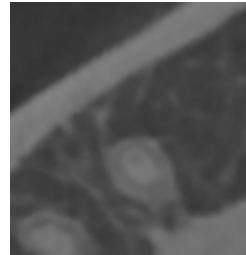
1 корень, 1 канал.



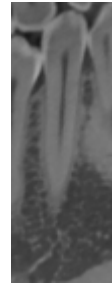
Axial



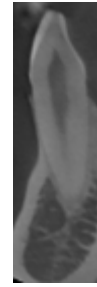Axial



Axial



Sagittal



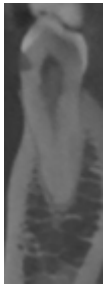Frontal



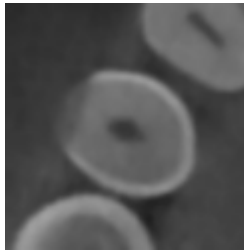
Зуб 44

1 корень, 1 канал.

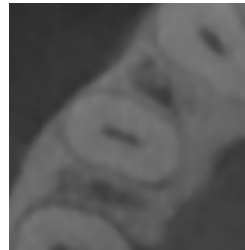
■ Абфракция



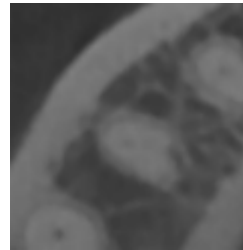
Frontal



Axial



Axial



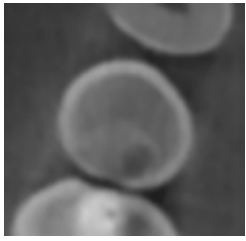
Axial



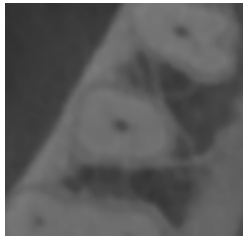
Зуб 45

1 корень, 1 канал, **Признаки кариеса.**

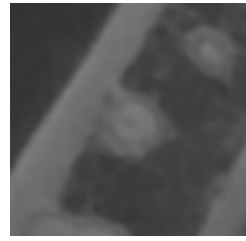
■ Абфракция



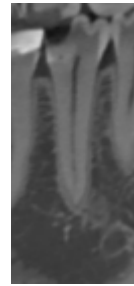
Axial



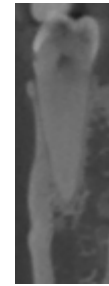Axial



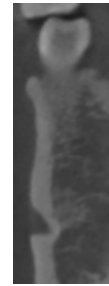Axial



Sagittal



Frontal

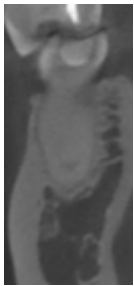


Frontal

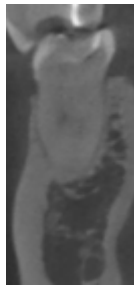

Зуб 46

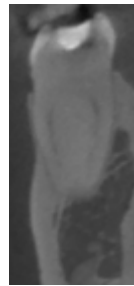
2 корня, 4 канала, **Пломба.**



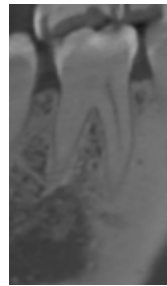
Frontal



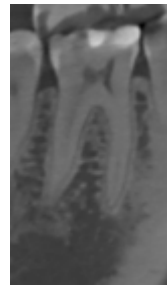
Frontal



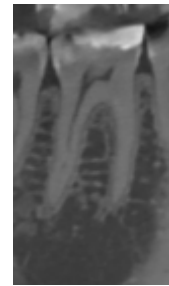
Frontal



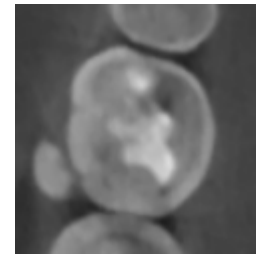
Sagittal



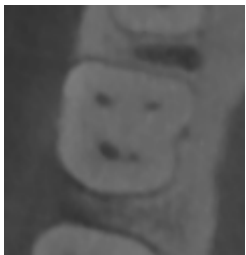Sagittal



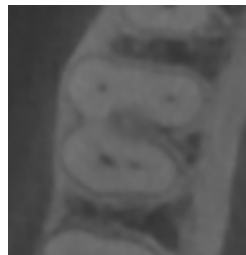
Sagittal



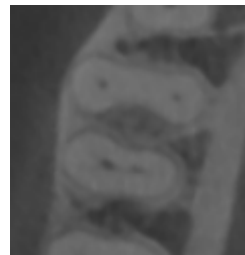Axial



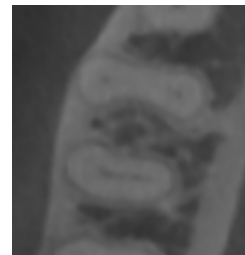
Axial



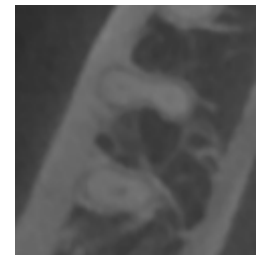
Axial



Axial



Axial



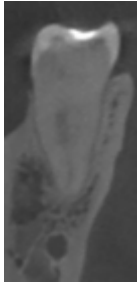Axial



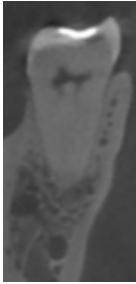Зуб 47

2 корня, 3 канала, Горизонтальная резорбция, Пломба, Признаки кариеса.

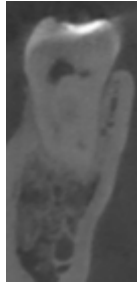Кариес под пломбой?



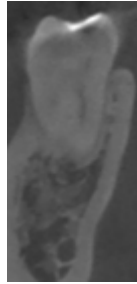
Frontal



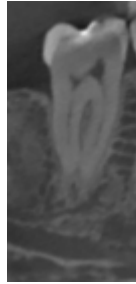
Frontal



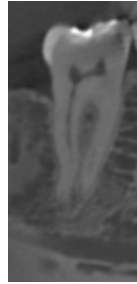
Frontal



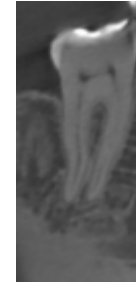Frontal



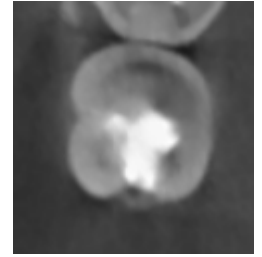
Sagittal



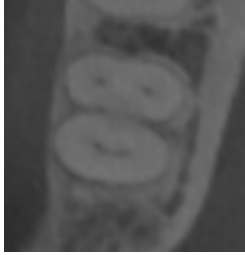Sagittal



Sagittal



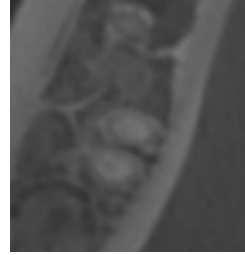
Axial



Axial



Axial



Axial

28.11.2019

Врач-рентгенолог, гл.врач
Грачев В.И.

